

# The 1450-nm diode laser for facial inflammatory acne vulgaris: Dose-response and 12-month follow-up study

Ming H. Jih, MD, PhD,<sup>a</sup> Paul M. Friedman, MD,<sup>a,b</sup> Leonard H. Goldberg, MD,<sup>a,c</sup>  
Michele Robles,<sup>a</sup> Adrienne S. Glaich, MD,<sup>a</sup> and Arash Kimyai-Asadi, MD<sup>a</sup>  
Houston, Texas

**Background:** The 1450-nm diode laser has been known to thermally alter sebaceous glands and has been found to be effective for the treatment of inflammatory facial acne.

**Objective:** Our aim was to evaluate the dose response of a 1450-nm diode laser for treatment of facial acne, sebum production, and acne scarring utilizing two laser fluences and to determine long-term remission after laser treatment.

**Methods:** Twenty patients (Fitzpatrick skin phototypes II-VI) received 3 treatments using the 1450 nm diode laser (3-4 week intervals). Split face comparisons were performed by randomizing patients to one of two fluences (14 or 16 J/cm<sup>2</sup>) on the right or left side of the face. Clinical photographs, lesion counts, and sebum measurements were obtained at baseline and after each treatment. Investigators' and patients' subjective evaluations of response to treatment were assessed.

**Results:** Percentage reductions in mean acne lesion counts from baseline were 42.9% (14 J/cm<sup>2</sup>) and 33.9% (16 J/cm<sup>2</sup>) after one treatment and 75.1% (14 J/cm<sup>2</sup>) and 70.6% (16 J/cm<sup>2</sup>) after 3 treatments. There was persistent reduction of 76.1% (14 J/cm<sup>2</sup>) and 70.5% (16 J/cm<sup>2</sup>) at the 12-month follow-up ( $P < .01$ ). Both objective and subjective improvements in acne scarring and sebum production were noted. Treatment-related pain was well tolerated, and adverse effects were limited to transient erythema and edema at treatment sites.

**Limitations:** This was a small study and comparison was limited to two laser fluences.

**Conclusion:** The 1450-nm diode laser reduced inflammatory facial acne lesions even in Fitzpatrick skin phototypes IV-VI with minimal side effects. Significant improvement in acne lesion counts were noted after the first treatment and was maintained 12 months after the third treatment, indicating significant long-term clinical remission after laser treatment. (J Am Acad Dermatol 2006;55:80-7.)

Light-based therapies for the treatment of acne have become increasingly common as an alternative to topical and oral medications in the quest for a safer, more effective, and more convenient treatment for acne. We have previously shown that treatment with an infrared 1450-nm diode

laser with a dynamic cooling device can safely and effectively reduce inflammatory acne lesions of the face with fluences as high as 14 J/cm<sup>2</sup>.<sup>1</sup> At a high fluence of 24 J/cm<sup>2</sup> in a rabbit ear model, this device has been shown to cause thermal coagulation of the sebaceous lobule and associated hair follicle through thermal heating of the mid dermis up to 500  $\mu\text{m}$  in depth. Although such a high degree of thermal injury and coagulation has not been observed at fluences lower than or equaling 14 J/cm<sup>2</sup>, the presumed mechanism of acne improvement is through heating of the sebaceous gland and associated structures. It is believed that this heating of the sebaceous gland and associated structures results in reduced sebaceous gland activity that subsequently leads to a reduction in inflammatory acne lesions. On the basis of the proposed mechanism of action, it is possible that

From DermSurgery Associates,<sup>a</sup> University of Texas School of Medicine,<sup>b</sup> and M. D. Anderson Cancer Center.<sup>c</sup>

Funding sources: Laser and patient stipend provided by Candela Corporation.

Disclosure: Dr Friedman has been a paid investigator for Candela Corporation.

Reprint requests: Ming H. Jih, MD, PhD, 7515 Main, Suite 220, Houston, TX 77030. E-mail: [mjih@dermsurgery.org](mailto:mjih@dermsurgery.org).

0190-9622/\$32.00

© 2006 by the American Academy of Dermatology, Inc.

doi:10.1016/j.jaad.2006.02.018

improved clinical outcomes may be achieved at fluences higher than the previously used fluence of 14 J/cm<sup>2</sup>. However, it is currently unknown whether any difference in clinical response related to efficacy and safety occurs at higher laser fluences. An additional unknown factor regarding laser treatment for acne is the duration of the remission that is obtained. Indeed, a common criticism of laser for the treatment of acne has been the lack of any documented length of remission after treatment. In addition, the studies to date have not specifically addressed the effect of the laser on sebum secretion, even though the main mechanism of action of this laser is thought to be mediated by its action on sebaceous glands. Heating of the infundibulum and associated sebaceous lobules is believed to result in both reductions in sebum production and inflammatory acne lesions.

The goals of the present study were to evaluate the clinical outcome of laser treatment utilizing two differing fluences and to examine the long-term outcome 1 year after the last laser treatment. In addition, objective measurement of the effect of the laser on sebum production was evaluated.

## METHODS

Twenty patients (10 women and 10 men) with active inflammatory facial acne vulgaris with Fitzpatrick skin phototypes II-VI were enrolled in the study. The presence of at least 20 active inflammatory acne lesions was required for inclusion in the study. Comedonal acne lesions were not evaluated in the study. The subject age range was 18 to 39 years (mean, 23 ± 6 years). Exclusion criteria included pregnancy, treatment with oral isotretinoin within the previous 6 months, commencement or alteration in the use of oral contraceptives during the previous 3 months, use of oral antibiotics in the previous 4 weeks, or the use of laser or light-based treatments for facial acne within the previous 6 months. Patients with tanned skin or a history of recent excessive sun exposure or sunburn were also excluded. Patients were allowed to continue their current topical medications during the study.

Split face comparisons of two laser fluences were performed by randomizing patients to one of two fluences (14 or 16 J/cm<sup>2</sup>) administered to the right or left side of the face. Topical lidocaine 5% (Ela-Max; Ferndale Laboratories, Ferndale, Mich) was applied 1 hour before laser treatment. The entire face from forehead to the jaw line was treated with non-overlapping single pulses of a 1450 nm diode laser (Smoothbeam, Candela Corporation, Wayland, Mass) with an integrated dynamic cooling device. Laser treatments were delivered by using a 6-mm spot size. The dynamic cooling device setting was 40 ms at

14 J/cm<sup>2</sup> and 45 ms at 16 J/cm<sup>2</sup>, which is split into 5 individual pulses before, during, and after the laser pulse. Immediately after the treatment, a moisturizing cream (M.D. Forte Replenish Hydrating Cream, Allergan Incorporated, Irvine, Calif) and sunscreen (M.D. Forte Aftercare Environmental Protection Cream SPF30, Allergan Incorporated) were applied to the treated skin. Patients were counseled to avoid sun exposure after the laser treatment and counseled to use a sunscreen with a sun protection factor of 30 daily. A total of 3 treatments were given at 3- to 4-week intervals.

Inflammatory acne lesions were counted and photographs were obtained by means of standardized settings and lighting with a stereotactic device and a 35-mm film camera (Canfield Scientific, Fairfield, NJ) at baseline and before each treatment and at each follow-up visit from the front and left and right sides at 45 degrees. Sebum production rate measurement was performed with the use of Sebutape (CuDerm Corporation, Dallas, Tex) at baseline and before each treatment session. The Sebutape was applied to the center of the forehead and allowed to remain on the skin for 1 hour after which the amount of sebum collected on the Sebutape was correlated to sebaceous gland activity by means of a calibrated numeric chart (scale of 1 to 5). Pain scores related to laser treatment were obtained based on a visual analog scale (VAS) at each treatment visit using a scale of 0 (no pain) to 10 (worst pain). Complications were assessed at each visit. Patients were clinically assessed for a total of 12 months with follow-up visits scheduled at 1, 3, 6, and 12 months after the final (third) laser treatment.

Evaluation of acne scarring was performed by assessment of patient photographs by 2 dermatologists using comparisons of baseline photographs to photographs obtained at the 3-, 6-, and 12-month follow-up visits. Improvements were graded on the following scale: (0: no improvement, 1: <25% improvement, 2: 26%-50% improvement, 3: 51%-75% improvement, 4: >75% improvement).

At the 1-, 3-, 6-, and 12-month follow-up visits, patients reported subjective ratings on acne and acne scars (0: worsening, 1: no change, 2: mild improvement, 3: moderate improvement, 4: marked improvement), and skin oiliness (0: undesirably less oily, 1: desirably less oily, 2: no change, 3: undesirably more oily).

## Statistical analysis

Patients were selected for the study on the basis of inclusion/exclusion criteria. The data for all patients were used in the statistical analysis and none were excluded from the analysis. The calculation of the

**Table I.** Percentage reductions in mean acne lesion counts from baseline

	14 J/cm <sup>2</sup>	16 J/cm <sup>2</sup>
Posttreatment 1	42.9% (4.6 × 10 <sup>-8</sup> )*	33.9% (2.1 × 10 <sup>-6</sup> )
Posttreatment 2	63.9% (6.9 × 10 <sup>-14</sup> )	48.4% (4.9 × 10 <sup>-8</sup> )
Posttreatment 3 (1-mo follow-up)	75.1% (1.5 × 10 <sup>-13</sup> )	70.6% (1.8 × 10 <sup>-11</sup> )
3-mo follow-up	88.6% (1.8 × 10 <sup>-15</sup> )	81.5% (3.3 × 10 <sup>-14</sup> )
6-mo follow-up	81.6% (2.6 × 10 <sup>-12</sup> )	84.1% (4.6 × 10 <sup>-14</sup> )
12-mo follow-up	76.1% (2.4 × 10 <sup>-9</sup> )	70.5% (9.9 × 10 <sup>-8</sup> )

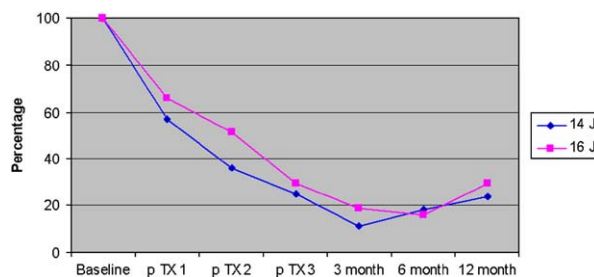
\**P* values in parentheses.

mean, standard deviation, and application of the Student *t* test (paired samples) was done through Microsoft Excel.

## RESULTS

All patients had reductions in acne lesion counts after laser treatment. The mean inflammatory lesion counts before treatment were 16.1 and 16.8 for the 14 and 16 J/cm<sup>2</sup> sides, respectively. Significant percentage reductions in mean acne lesion counts from baseline were obtained as early as after the first treatment, with 42.9% reduction seen at 14 J/cm<sup>2</sup> ( $P = 4.6 \times 10^{-8}$ ) and 33.9% reduction at 16 J/cm<sup>2</sup> ( $P = 2.1 \times 10^{-6}$ ). None of the patients experienced worsening of their acne after the first laser treatment. With subsequent treatments, additional improvements in acne lesion counts were seen with reductions of 63.9% (14 J/cm<sup>2</sup>,  $P = 6.9 \times 10^{-14}$ ) and 48.4% (16 J/cm<sup>2</sup>,  $P = 4.9 \times 10^{-8}$ ) after the second treatment and 75.1% (14 J/cm<sup>2</sup>,  $P = 1.5 \times 10^{-13}$ ) and 70.6% (16 J/cm<sup>2</sup>,  $P = 1.8 \times 10^{-11}$ ) after the third treatment. Persistent significant reductions in acne lesion counts were maintained at the 3-, 6-, and 12-month follow-up visits (Table I, Fig 1). Figs 2 through 5 demonstrate representative pretreatment and posttreatment clinical photographs of patients.

Sebutape scores decreased significantly from 3.3 at baseline to 2.95 ( $P = .03$ ) after the first treatment and 2.74 after the second treatment ( $P = .01$ ), correlating with objectively measurable decreases in sebum production. Although still decreased at 3.0 after the third treatment, this was not significantly lower than baseline. However, the lack of statistical significance may be due to the decreased sample number from 19 after the second treatment to only 7 after the third treatment. The lower sample number was mainly due to the fact that after the third and last laser treatment, the patients did not have to prepare



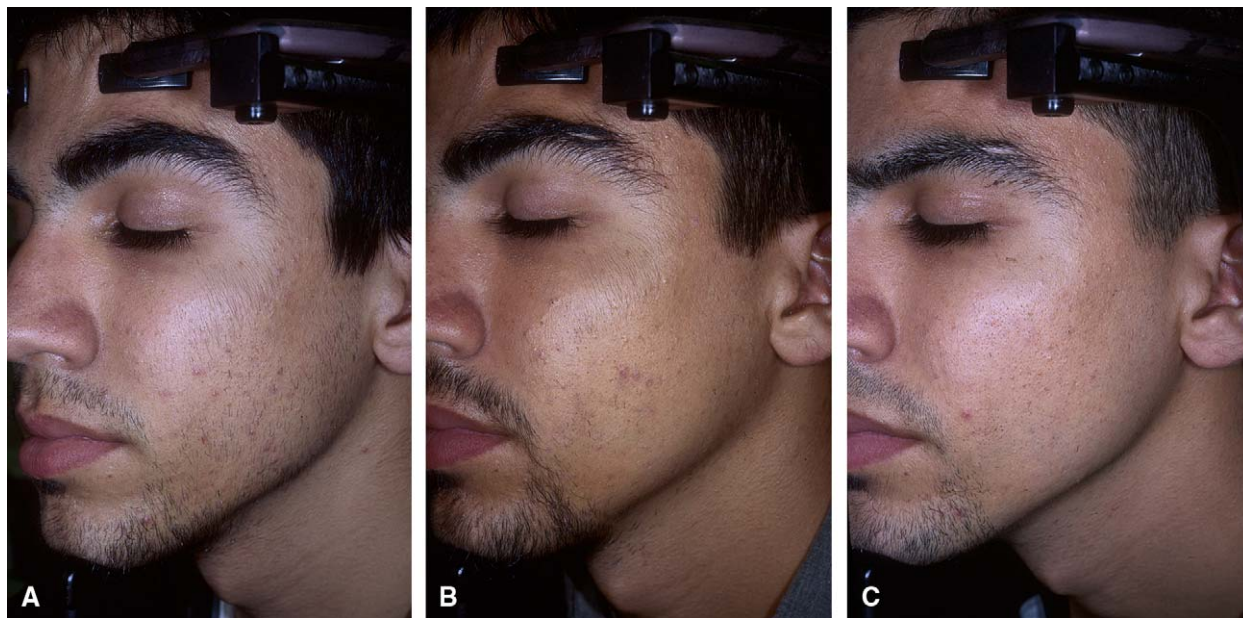
**Fig 1.** Percentage reduction in mean inflammatory acne lesion count after 1, 2, and 3 treatments, and at 1, 3, 6, and 12-month follow-up visits with 1450-nm diode laser. J, Joules (per cm<sup>2</sup>); p, post; TX, treatment.

their skin for a laser treatment, resulting in patients forgetting to apply the Sebuptape to their forehead 1 hour before the office visit.

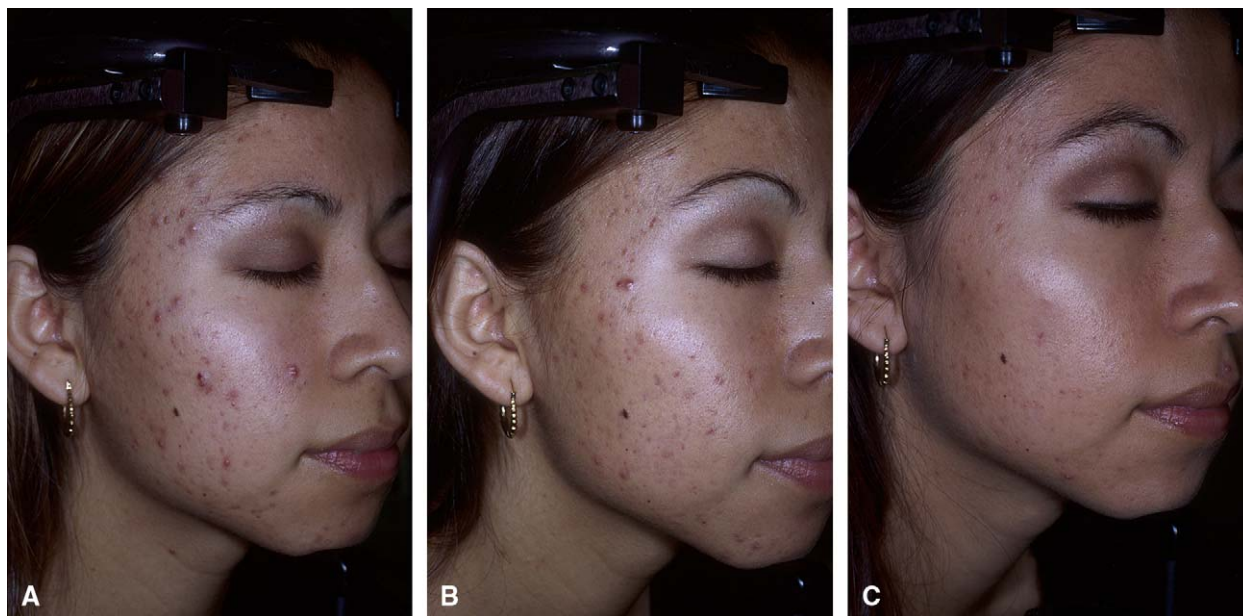Pain related to laser treatment was rated as moderate by the majority of patients with pain scores ranging from 4.4 to 5.5 throughout the treatment period. A slightly significant higher pain score was seen at the higher fluence of 16 J/cm<sup>2</sup> (VAS score, mean 5.5) compared with 14 J/cm<sup>2</sup> (VAS score mean 4.8;  $P = .03$ ) during the first treatment session; thereafter there were no statistically significant differences in treatment-related pain at the two fluences. No treatment session was discontinued because of pain.

Improvement in acne scarring was assessed by two dermatologists (A. K. A. and P. F.) using comparison of baseline photographs to photographs obtained at the 3-, 6-, and 12-month follow-up visits. No significant difference in acne scarring improvement was noted between patients treated at 14 versus 16 J/cm<sup>2</sup> at any follow-up time points (Table II). At the 3-month follow-up visit, patients on average had less than 25% improvement in acne scarring. Further significant improvements in acne scarring were seen at the 6-month follow-up visit, with an average of 26% to 50% improvement noted for both fluences tested ( $P = .01$ ). Compared with the 6-month follow-up, additional significant improvements in acne scarring were seen at the 12-month follow-up visit for patients treated at 16 J/cm<sup>2</sup> but not for those treated at 14 J/cm<sup>2</sup> ( $P = .01$ ).

In terms of patient subjective assessment of acne improvement, the vast majority of patients (94.1%) noted some improvements in their acne as early as 1 month after the last laser treatment, which was maintained at the 3-month (97.1%), 6-month (96.7%), and 12-month (100%) follow-up visits (Fig 6). In fact, the majority of patients graded the improvement in facial acne as being moderate to marked at all survey time points with 85.3% at the 1-month, 67.7% at the



**Fig 2.** **A**, Left cheek, pretreatment, with inflammatory papules and pustules. **B**, Reduction in inflammatory lesions after 3 treatments with the 1450-nm diode laser. **C**, Appearance at 12-month follow-up.

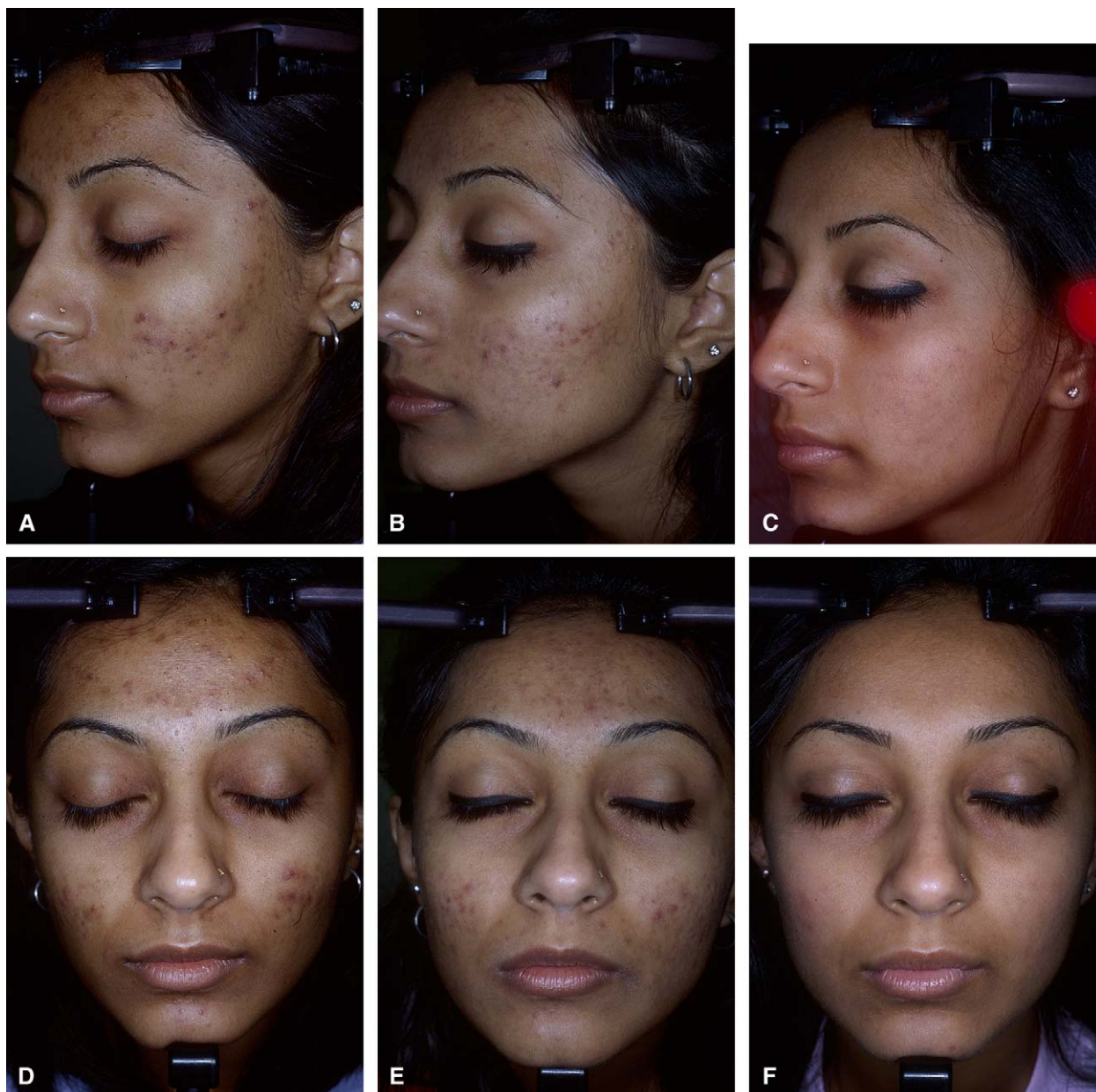

**Fig 3.** **A**, Multiple inflammatory papules and few scattered pustules on right cheek pretreatment. **B**, After 3 treatments with 1450-nm diode laser. **C**, Appearance at 12-month follow-up.

3-month, 60.0% at the 6-month and 82.1% at the 12-month follow-up visits.

Similar results were noted for patient subjective assessment of improvement in acne scarring, with the majority of patients noting at least mild improvement in acne scarring as early as the 1-month follow-up visit (88.2%) with continued improvements noted at the 3-month (79.4%), 6-month (93.3%) and 12-month

(85.9%) follow-up visits (Fig 6). Moderate to marked improvements in acne scarring were noted at the 1-month follow-up visit by 47.1% of patients, at the 3-month follow-up by 58.8% of patients, at the 6-month follow-up by 70.0% of patients, and at the 12-month follow-up by 46.5% of patients. Subjective assessment of skin oiliness revealed that the majority of patients noted desirably less oily skin after laser



**Fig 4.** **A**, Left cheek pretreatment with inflammatory papules and pustules. **B**, After 3 treatments with 1450-nm diode laser. **C**, Appearance at 12-month follow-up. **D**, Frontal view before treatment. **E**, Frontal view at 1-month follow-up. **F**, Frontal view at 12-month follow-up.

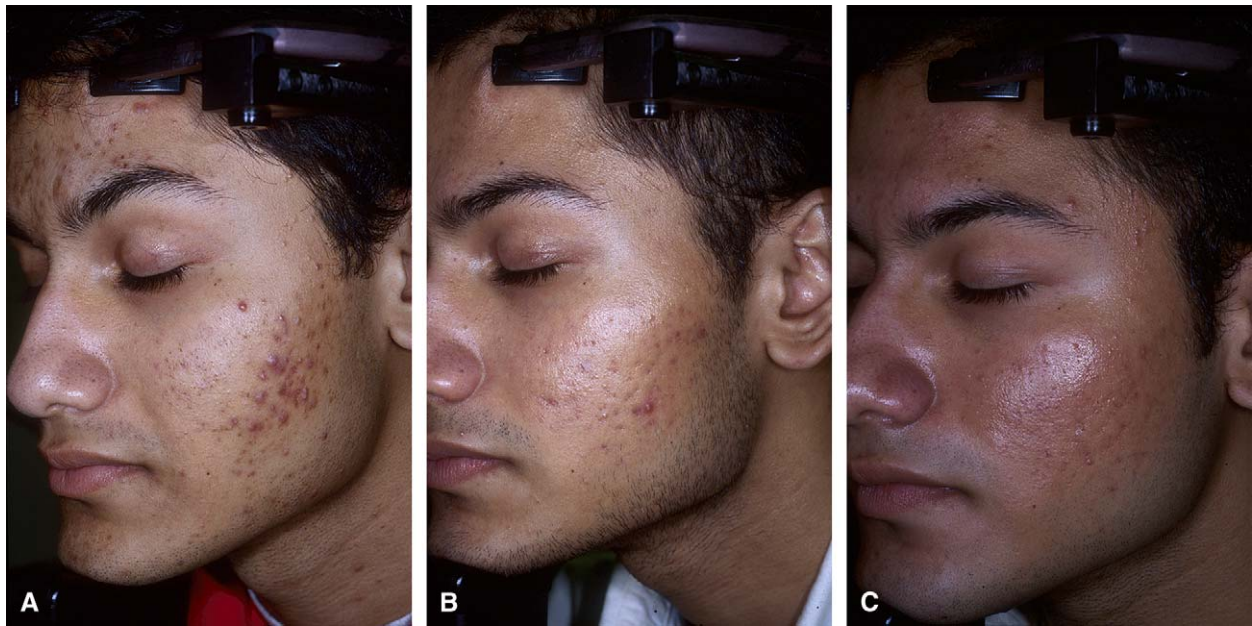
treatments at 1 month (76.%), 3 months (85.3%), and 6 months (73.3%), with the remainder of patients noting no change in skin oiliness (Fig 6). By the 12-month follow-up visit, only 46.4% of patients stated that their skin remained desirably less oily, with 53.6% of patients noting no change in skin oiliness from baseline. However, no patients at any time noted undesirably less oily skin after laser treatment.

For both fluences of 14 and 16 J/cm<sup>2</sup>, the most common side effect was transient erythema and edema at the treatment sites, which in most patients

lasted from several hours up to 24 hours. No adverse effects such as pigmentary alteration, scarring, or infection were observed even in those patients with Fitzpatrick skin phototypes IV-VI.

#### DISCUSSION

Clinical observation and anecdotal reports have indicated that higher laser fluences may result in improved acne clearing with the 1450-nm diode laser. However, the optimal laser treatment parameters have not been determined. Currently, 14 J/cm<sup>2</sup>



**Fig 5.** A, Left cheek pretreatment with inflammatory papules and pustules. B, After 3 treatments with 1450-nm diode laser. C, Appearance at 12-month follow-up.

is the highest fluence available on the commercial 1450-nm diode laser. A prototype laser obtained from Candela Corporation (Wayland, Mass) allowed us to treat at a higher fluence of  $16 \text{ J/cm}^2$ . Both fluences significantly reduced inflammatory acne lesion counts. However, the results of the current study show that reductions in inflammatory acne lesion counts were similar at the fluences ( $14$  and  $16 \text{ J/cm}^2$ ) tested. The lack of any statistically significant different reductions in acne lesions with the two fluences may be due to the similarity of the two fluences chosen for the study. It is conceivable that a comparison of two more disparate laser energy levels would have revealed a statistically significant difference in acne lesion reduction. However, the results of the current study do clearly show that the highest fluence currently available on the 1450-nm diode laser is very effective for the treatment of inflammatory acne. Another key finding was the absence of any increased adverse events at the higher fluence of  $16 \text{ J/cm}^2$  tested. Patients with all skin types including Fitzpatrick skin phototypes IV-VI tolerated both fluences well without any postinflammatory pigmentary alteration or scarring. Hence treatment with the lower fluence of  $14 \text{ J/cm}^2$ , which is the highest fluence available on the commercially released machine, optimizes clinical efficacy while providing a greater margin of safety.

Objective decreases in sebum production were seen even after the first laser treatment with the use of Sebutape measurements. This measurable decrease was correlated with a subjective report of

“desirably less oily skin” by a majority of the patients. Additional objective sebum measurements were not carried out during the follow-up period after the last laser treatment because subjects had difficulty remembering to place the Sebutape on the skin 1 hour before the office visit when not preparing their skin for a laser treatment. However, the majority of patients ( $>70\%$ ) reported subjectively decreased oiliness in their skin at the 1-, 3-, and 6-month follow-up visits, and 50% of patients continued to report subjectively decreased oiliness of their skin at the 12-month follow-up visit. Many of the subjects who suffered from both acne and oily skin rated the effect of the laser on sebum reduction as a highly desirable feature of laser treatment. Moreover, none of the patients developed “undesirably dry skin” from the laser treatment. Thus the laser is similar to oral isotretinoin in reducing sebum production while not resulting in the unwanted excessive dryness often associated with oral isotretinoin. Both the objective and subjective decreases in sebum production correlate well with the mechanism of action of selective photocoagulation of sebaceous glands by the 1450-nm diode laser.

Previously, Paithankar et al<sup>2</sup> reported remissions of up to 6-months in patients treated for acne lesions on the back with the 1450-nm diode laser. Our results show maintenance of significant reductions in inflammatory facial acne lesion counts from baseline even 12 months after the third and last laser treatment. This duration of remission is longer than that typically seen with oral antibiotics and compares

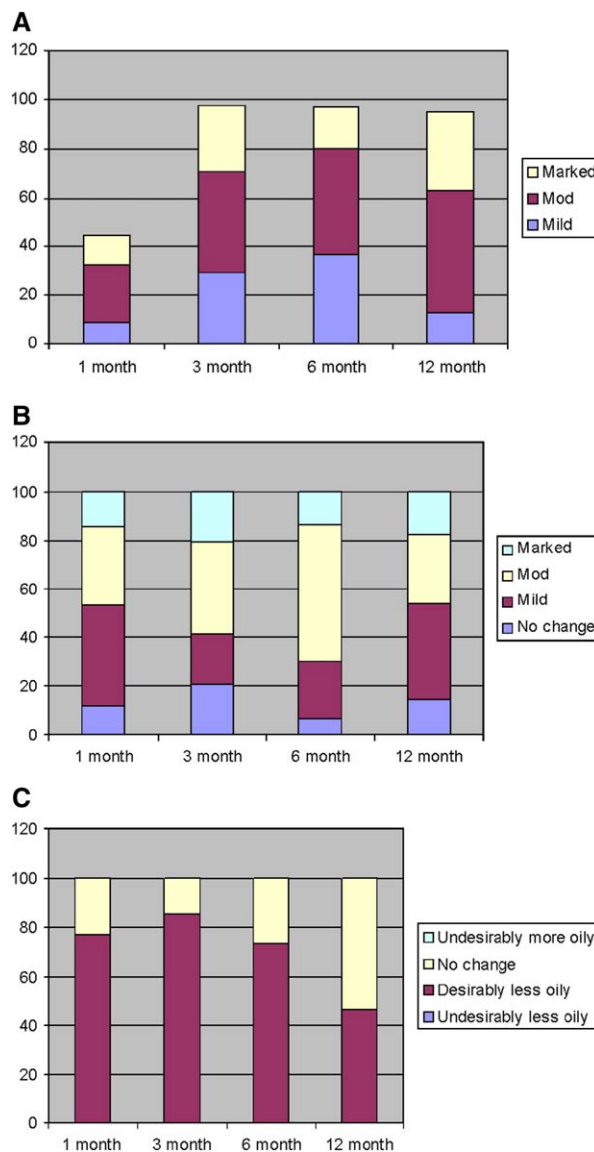
**Table II.** Acne scarring assessment scores

	14 J/cm <sup>2</sup>	16 J/cm <sup>2</sup>
3-mo follow-up	1.79 ± 0.46	1.75 ± 0.43
6-mo follow-up	2.13 ± 0.41	2.19 ± 0.69
12-mo follow-up	2.60 ± 0.63	2.50 ± 0.77

Scoring: 1, <25% improvement; 2, 26%-50% improvement; 3, 51%-75% improvement; 4, >75 improvement.

favorably with remissions obtainable with oral isotretinoin. Previous histologic studies did not demonstrate any long-term alteration in adnexal structure architecture, but it remains possible that thermal alteration of the follicular infundibulum and sebaceous lobules results in long-term alteration in the quantity or quality of sebaceous gland activity, with an associated reduction in inflammatory acne lesions.<sup>2</sup> The clinical efficacy and length of remission obtained with the laser is particularly significant given the favorable side-effect profile of the laser compared with both oral antibiotics and oral isotretinoin. The transient erythema and edema seen after laser treatment generally resolved within a day, and there were no sustained or long-term sequelae associated with this laser in our patients. The convenience of 3 laser treatments compared with daily oral medications over several months is also a distinct advantage of the laser, allowing for enhanced patient compliance. Moreover, the cost of 3 laser treatments compares favorably with the cost of other acne treatments provided over a 1-year period or to a 20-week course of oral isotretinoin.

In our study, after premedication with Ela-Max 5% cream under occlusion 1 hour before each treatment, every patient was able to tolerate the treatment-related pain. On average pain was rated as moderate. A slightly higher pain score was seen with treatment at 16 J/cm<sup>2</sup> (mean VAS score 5.5) compared with 14 J/cm<sup>2</sup> (mean VAS score 4.8) but only during the first treatment session. Thereafter pain was rated as similar between the two fluences. Although treatment pain does increase at higher fluences, most patients were unable to distinguish between the two fluences tested. Again, this may be due to the close proximity of the two fluences selected for the study. Most patients also tend to experience greater pain at the first treatment session because of trepidation about the initial treatment. In addition, the presence of more inflammatory lesions during the initial treatment also contributes to increased pain. As laser treatment progresses and the number of inflammatory lesions diminishes, the patients experience less pain with the subsequent treatments. The fluences used in the study are higher than what many physicians use in practice because of concern about



**Fig 6.** **A**, Patients' subjective assessment of improvements in inflammatory acne. **B**, Patients' subjective assessment of improvements in acne scarring. **C**, Patients' subjective assessment of improvements in skin oiliness.

treatment-related pain. In fact, many physicians start patients off at lower fluences (10-12 J/cm<sup>2</sup>) and gradually increase the fluence with each treatment session. However, our results show that the patients routinely tolerate treatment at the highest fluence (14 J/cm<sup>2</sup>) currently available even with the first treatment session.

Nonablative lasers, including the 1450-nm diode laser, have been shown to cause remodeling of dermal collagen, which can reduce the appearance of superficial acne scars.<sup>3-5</sup> All patients had both objective and subjective improvement in acne scarring with both laser fluences tested in our study. In contrast to topical or oral medications, laser

treatment has the unique advantage of simultaneously treating both the inflammatory acne lesions as well as the acne scars. Improvements in acne scarring occurred as early as 1 month after the last laser treatment but were more significant at the 6- and 12-month follow-up visits, thereby indicating that ongoing collagen remodeling long after the last laser treatment contributes significantly to improvements in acne scarring.

The 1450-nm diode laser was effective and safe in treating inflammatory facial acne in all skin types. Sebum reduction and improvements in acne scarring were also significant additional benefits of the laser treatment. In fact, the long-term remission achievable with laser treatment along with the uniform clinical efficacy and minimal adverse effects make the 1450-nm diode laser a suitable first-line, second-

line, or adjuvant treatment modality for moderate to severe acne.

#### REFERENCES

1. Friedman PM, Jih MH, Kimyai-Asadi A, Goldberg LH. Treatment of inflammatory facial acne vulgaris with the 1450-nm diode laser: a pilot study. *Dermatol Surg* 2004;30:147-51.
2. Paithankar DY, Ross EV, Saleh BA, Blair MA, Graham BS. Acne treatment with a 1,450 nm wavelength laser and cryogen spray cooling. *Lasers Surg Med* 2002;31:106-14.
3. Tanzi EL, Alster TS. Comparison of a 1,450 nm diode laser and a 1320 nm Nd:YAG laser in the treatment of atrophic facial scars: a prospective clinical and histologic study. *Dermatol Surg* 2004;30:152-7.
4. Sawcer D, Lee HR, Lowe NJ. Lasers and adjunctive treatments for facial scars: a review. *J Cutan Laser Ther* 1999;1:77-85.
5. Friedman PM, Jih MH, Skover GR, Payonk GS, Kimyai-Asadi A, Geronemus RG. Treatment of atrophic facial acne scars with the 1064-nm Q-switched Nd:YAG laser: six-month follow-up study. *Arch Dermatol* 2004;140:1337-41.

## DERMATOLOGY AS SHE IS SPOKE

---

### Euro—what?

A patient was referred to our clinic for treatment of a red, itchy rash on her face. She stated that another physician had made a diagnosis of “Eurosphilis” and she was sent to us for further care. She denied having unprotected sexual contact and also denied ever having visited Europe. But, she had been using a new cosmetic product prior to the eruption. Our diagnosis was contact dermatitis. After one week of mild topical corticosteroid treatment and avoidance of the facial product (which was also not from Europe,) the rash resolved. At her follow-up appointment she was told to avoid the facial product she had been using, that she had neither erysipelas (nor “Eurosphilis,”) and to be leery of amorous Europeans.

*Jeremy S. Bordeaux, MD, MPH*  
*Mary E. Maloney, MD*  
*University of Massachusetts Medical School*  
*Worcester, Massachusetts*

doi:10.1016/j.jaad.2005.12.029