

Laser Treatment of Eyelid Laxity Using the Smoothbeam® 1450 nm Diode Laser


Mark B. Taylor, M.D. and
Nancy J. Samolitis, M.D.
Gateway Aesthetic Institute &
Laser Center,
Salt Lake City, Utah

Introduction

Non invasive surgical techniques have been growing in popularity among cosmetic patients as technology continuously advances. One of the most common complaints we hear from patients in our practice is that they are unhappy with the aged appearance and sagging look of their upper and lower eyelids. Skin laxity is usually associated with features of rough skin texture, wrinkles around the skin and “baggy” eyelids.

Blepharoplasty has traditionally been used to remedy the skin laxity complaint. It is an excellent procedure to eliminate excess eyelid skin, and ablative laser resurfacing effectively smoothes the texture and rhytids; however, these are expensive procedures that require prolonged healing time and have an increased risk of scarring and dyspigmentation. Another potential issue or complication with blepharoplasty is that patients with poor lid tone or laxity of the lateral canthus may need adjunctive procedures in order to prevent postoperative scleral show or ectropion post-surgery.

In our practice, noninvasive aesthetic procedures are becoming more popular because of the reduced risk of infection and reduction in downtime post-procedure. Nonablative lasers and radiofrequency devices are being used more commonly to firm and tighten the skin and improve the appearance of fine lines and poor skin elasticity on the face and body.



Mark B. Taylor, M.D.
Nancy J. Samolitis, M.D.



The Smoothbeam laser is a 1450 nm diode with a Dynamic Cooling Device™ (DCD™). This infrared laser targets water and causes thermal injury to the dermis, while the cooling device increases patient comfort and prevents injury to superficial tissue. The depth of penetration achieved by this laser is 300 mm, making it an ideal choice for treatment of the thin skin of the eyelids in contrast to lasers such as an Nd:YAG, which would be unsafe to use in the orbit because of deeper penetration. We hypothesize that the heat produced in the dermis of the eyelid skin causes contraction of dermal fibers and subsequent collagen remodeling in the wound healing process, ultimately leading to the clinical appearance of tighter, smoother skin. We have successfully demonstrated that Smoothbeam treatment demonstrates an improvement in eyelid laxity, while offering a significantly reduced risk of side effects as well as a faster recovery time versus invasive surgery.

Prior to treatment to keep patients as comfortable as possible, we typically anesthetize the area to be treated with a 45–60 minute incubation period of a topical anesthetic, such as a compounded 6% lidocaine and 6% tetracaine cream. We then use proparacaine drops to anesthetize the eye before using a lubricant eye gel and inserting intraocular metal eye shields. Typical settings are 4–6 mm spot size, 10–15 J/cm², and a DCD setting of 40 for patients with Fitzpatrick skin Types I–III.



CLINICAL BULLETIN

No. 8

Generally, we will use three passes over the upper and lower eyelids, extending from the eyebrow laterally, following the orbital rim, and moving down to the malar cheek on the lower eyelid. Lower fluences and ice instead of DCD should be used with patients with skin Types IV and higher. Caution should be used in any patient who has a history of hyperpigmentation, and the DCD should be adjusted accordingly. The treatment should be repeated every 8 to 12 weeks and a series of four to six treatments is recommended for optimum results.

We commonly use the 1450 nm diode laser in our clinical practice for skin rejuvenation in treating fine lines and wrinkles, so it makes sense to use this modality for treating eyelid laxity in patients who wish for a nonsurgical treatment. We currently have two ongoing split-face studies to further illustrate the efficacy of Smoothbeam in treating skin laxity with positive preliminary data.

To date, patients have expressed a high satisfaction with the results of this treatment. Post-operatively, patients typically have mild erythema and edema in the treated area lasting 24 to 48 hours. We have not seen any long-term adverse effects.

Most patients see results within three to six months after the first treatment. As can be seen in the figures, results include relief of sagging skin of the lower eyelids, smoothing of eyelid rhytids, and overall tightening of skin.

In our experience, the 1450 nm diode laser is a safe and effective treatment for eyelid laxity with minimal risk and recovery time. This is also a good treatment to use in combination with other minimally invasive techniques, such as injectable neuromodulators and fillers.

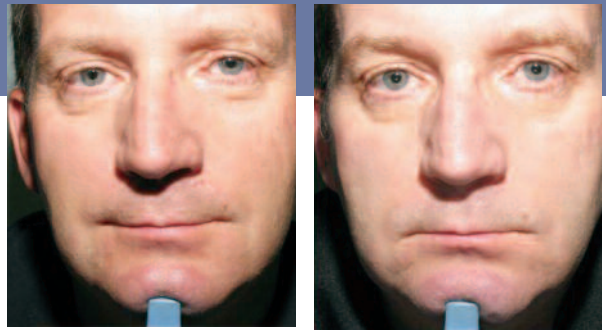

Figure 1. Only left eye treated in split face study, post five treatments.

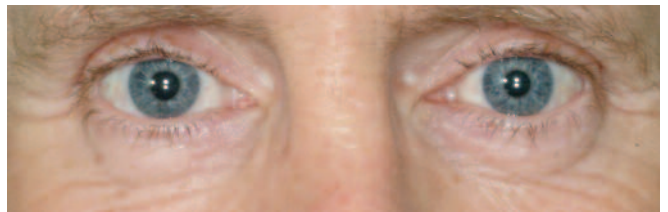
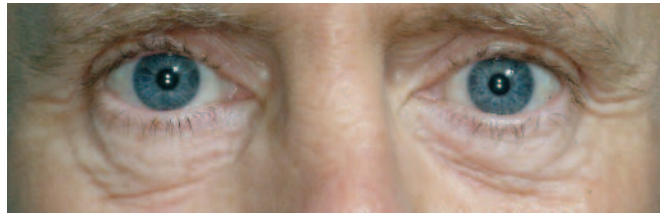
Figure 2. Top: pretreatment, bottom: post-treatment.

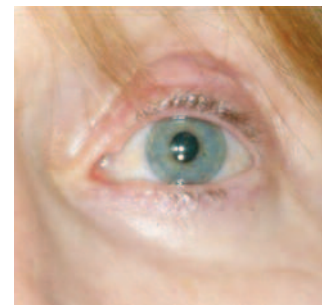
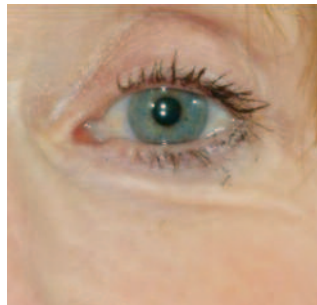
Figure 3. Left eye pretreatment and post-treatment.

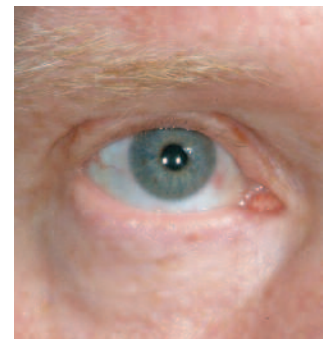
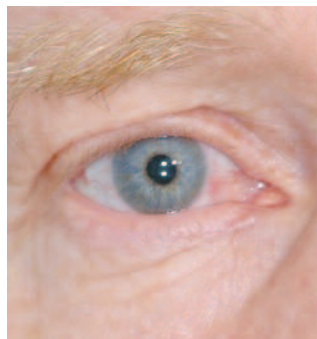
Figure 4. Right eye pretreatment and post-treatment.

Treatment parameters are subject to change—please consult your sales representative or clinical consultant, or visit www.mycandela.com to obtain current information regarding the use of your Candela device.

Smoothbeam is a registered trademark of Candela Corporation. Dynamic Cooling Device and DCD are trademarks. To find out more about Candela and its products, contact your authorized Candela representative or call toll-free worldwide (800) 821-2013. Dial USA country code if calling internationally. ©2007 Candela Corporation. All rights reserved. Printed in the USA. 07/07 0920-23-0861 Revision 01



CANDELA[®]

Candela Corporation
530 Boston Post Road
Wayland, MA 01778 USA
Phone: (508) 358-7637
Fax: (508) 358-5569
Toll-Free: (800) 821-2013
www.candelalaser.com