



Maria Cristina Mansur, M.D.

GentleLASE® Treatment of Venous Lake

Maria Cristina Mansur, M.D.
Medical Director, Department of
Dermatology Centro Científico de
Medicina Cutânea—MG;
Professor, Universidade Federal de
Juiz de Fora—MG, Brazil

Introduction

Venous lakes are dark blue, slightly elevated, dome-shaped lesions composed of a dilated, blood-filled vascular channel. They are a form of senile angioma. Histologically, they consist of greatly dilated, thin-walled venules without the proliferation of vascular tissue of the true angioma. There is degeneration of the supporting connective tissue. They are common on sun-exposed surfaces of the vermilion border of the lip and the ears. Elastosis of the walls of vessels due to actinic damage appears to cause weakening of the vessel wall and its subsequent dilatation. They occasionally bleed following trauma and can be removed by electrodesiccation, with the argon, copper and pulsed dye laser.

Method

I have treated multiple patients (Fitzpatrick skin types I-II) with venous lakes on the lips with the GentleLASE alexandrite laser from Candela with surprisingly good results after only two treatments. I treated all the patients with the 12 mm spot, 30 J/cm², Dynamic Cooling Device™ (DCD™) 60 msec spray and 50 msec delay, double pulsing, with a monthly interval between treatments. A topical anesthetic was applied prior to treatment to reduce patient discomfort, which was reported as minimal.

Results

The venous lakes darkened significantly and scabbed four days following the initial treatment. However, after two sessions with a one-month interval, these three patients demonstrated complete clearance using 755 nm energy and 3 msec pulse duration of the GentleLASE alexandrite laser. There was no pain reported following the laser treatments.

Discussion

Whereas pulsed dye lasers—with their relatively higher hemoglobin absorption coefficient—are more typically reported as being the laser of choice to treat cutaneous vascular lesions, thicker malformations are more difficult to treat with the relatively short 585-595 nm wavelength energy of the pulsed dye laser.

The GentleLASE alexandrite laser at 755 nm seems to satisfy the dual requirement for treating more substantial vascular lesions—good hemoglobin absorption and longer, more deeply penetrating wavelength energy.

In addition to fewer treatments (two!) required to clear the condition, using the GentleLASE laser also allows for DCD safety and comfort. The GentleLASE laser uses an adjustable cryogen spray to protect the patient's skin and minimize patient discomfort during the laser procedure.



Treating venous lakes, and thicker vascular lesions in general, is yet another example of the treatment versatility of the GentleLASE laser from Candela.

References

- 1- Kavanagh, G.M., Bradfield, J.W.B., et al. "Weathering nodules of the ear: a clinico-pathological study." *Br J Dermatol*, 135 (1996) 550-4.
- 2- Goldberg, L.H., Altman, A.R. "Venous lakes of the ears." *Cutis*, (1985) 472-473.
- 3- Neumann, R.A., Knobler, R.M. "Venous lakes (Bean-Walsh) of the lips-treatment experience with the argon laser and 18-month follow-up." *Clin Exp Dermatol*, 15 (1990) 115-118.
- 4- Gonzalez, E., Gange, R.W., et al. "Treatment of telangiectases and other benign vascular lesions with the 577 nm pulsed dye laser." *J Am Acad Dermatol*, 27 (1962) 220-226.

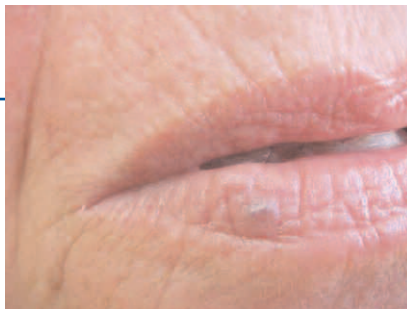
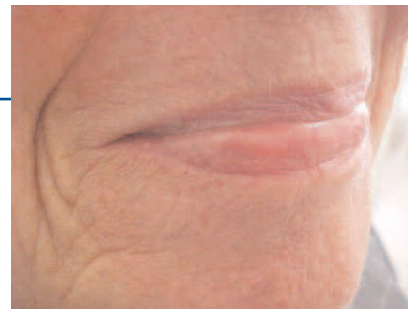

Figure 1—Case 1 Pretreatment.



Post-treatment.

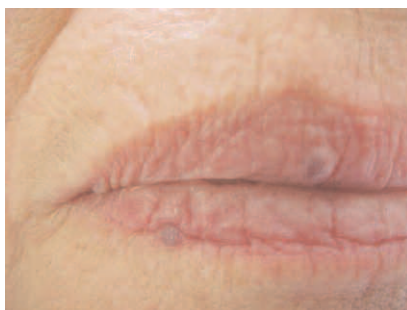
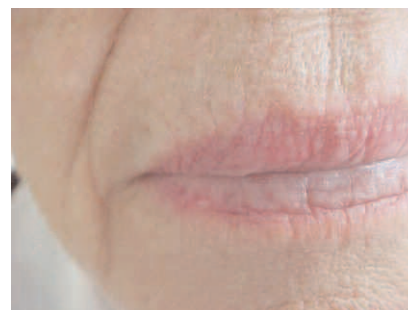
Figure 2—Case 2 Pretreatment.



Post-treatment.

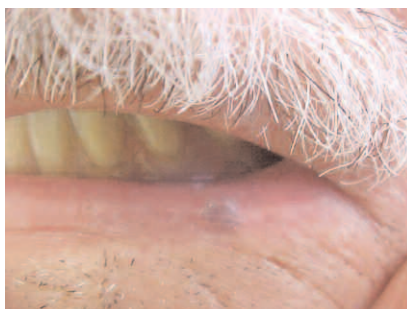
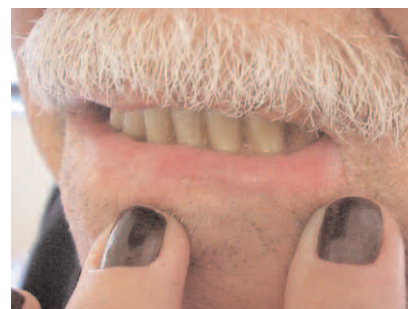
Figure 3—Case 3 Pretreatment.



Post-treatment.

